

# Recurrence following Treatment of Ductal Carcinoma in Situ with Skin-Sparing Mastectomy and Immediate Breast Reconstruction

Aldona J. Spiegel, M.D., and Charles E. Butler, M.D.

Houston, Texas

Skin-sparing mastectomy with immediate breast reconstruction can provide an excellent cosmetic result. Despite its increasing popularity, few studies have assessed the risk of recurrence when the procedure is used for the treatment of ductal carcinoma in situ. To evaluate the oncologic safety of skin-sparing mastectomy used for the treatment of ductal carcinoma in situ, the recurrence rate was analyzed. Patients with ductal carcinoma in situ or invasive carcinoma or both who underwent skin-sparing mastectomy with immediate breast reconstruction between 1985 and 1994 and had a follow-up period of at least 6 years were included in this retrospective analysis. The recurrence rates were determined for invasive carcinoma (with or without foci of ductal carcinoma in situ) and ductal carcinoma in situ alone. A total of 221 patients were included, 177 patients with invasive carcinoma and 44 patients with ductal carcinoma in situ alone. The immediate breast reconstructions were performed with transverse rectus abdominis muscle (TRAM) flaps in 62 percent of patients, implants in 34 percent of patients, and latissimus dorsi myocutaneous flaps (with or without implants) in 4 percent of patients. The local recurrence rate was zero of 44 for patients with ductal carcinoma in situ and 5.6 percent (10 of 177) for patients with invasive carcinoma during a mean follow-up period of 9.8 years. There was a 6.8 percent (12 of 177) metastatic recurrence rate in the invasive carcinoma group. All recurrences were invasive ductal carcinoma. Of the patients with ductal carcinoma in situ alone, none developed metastatic disease. The combined metastatic and local recurrence rates for the invasive carcinoma group ( $n = 177$ ) with each type of reconstruction were 13 percent (14 of 110), 12 percent (seven of 60), and 14 percent (one of seven) for TRAM flaps, implants, and latissimus dorsi flaps, respectively. The risk of recurrence following skin-sparing mastectomy and immediate breast reconstruction for ductal carcinoma in situ is low during this follow-up period. Therefore, skin-sparing mastectomy with immediate breast reconstruction seems to be a safe oncologic treatment option for ductal

carcinoma in situ; however, a longer follow-up period is important to determine the long-term risk of recurrence. (*Plast. Reconstr. Surg.* 111: 706, 2003.)

Before the use of mammography for breast cancer screening, ductal carcinoma in situ was believed to have a relatively low incidence. However, it is currently the fastest growing subgroup of breast neoplasia, making the determination of proper management an increasingly important issue.<sup>1</sup> More than 60 percent of cases are discovered solely by mammography.<sup>2</sup> Usually, high-quality mammography can detect small, nonpalpable lesions by visualizing calcium deposits that form as a result of tumor cell necrosis. Ductal carcinoma in situ is defined as proliferating malignant ductal cells limited to existing ductal units, without invasion through the basement membrane.<sup>3</sup> Hypothesized to be the primary stage of carcinoma in a multistep process of carcinogenesis, ductal carcinoma in situ includes a heterogeneous group of lesions with various morphologic and biological attributes. Patients who have multifocal ductal carcinoma in situ with microinvasion have a 5-year disease-free survival rate of 78 percent, compared with 98 percent in patients with simple ductal carcinoma in situ.<sup>4</sup>

For breast cancer patients undergoing immediate reconstruction, skin-sparing mastectomy has become increasingly popular because

From the Department of Plastic Surgery, The University of Texas, M. D. Anderson Cancer Center. Received for publication January 29, 2002; revised April 17, 2002.

DOI: 10.1097/01.PRS.0000041440.12442.05

it preserves the native breast skin envelope and, thus, facilitates a superior reconstructive result. The oncologic safety of skin-sparing mastectomy has been assessed for patients with invasive carcinoma, and local recurrence rates are similar following skin-sparing mastectomy, compared with nonskin-sparing mastectomy.<sup>5,6</sup>

Ductal carcinoma in situ has different characteristics and recurrence rates compared with invasive carcinoma, and no reported study has evaluated local recurrences following skin-sparing mastectomy and reconstruction performed for ductal carcinoma in situ. To address the question of the oncologic safety of skin-sparing mastectomy in patients with ductal carcinoma in situ, we retrospectively reviewed our experience with immediate breast reconstruction and local recurrence in patients with ductal carcinoma in situ and invasive carcinoma during a 10-year period.

#### PATIENTS AND METHODS

All patients with ductal carcinoma in situ or invasive carcinoma (pathologic stage II or lower) or both who underwent immediate breast reconstruction following skin-sparing mastectomy between 1985 and 1994 were identified from a comprehensive departmental database at the University of Texas M. D. Anderson Cancer Center. All of the 221 patients identified were followed up for at least 6 years, with no patients lost to follow-up.

A skin-sparing mastectomy was strictly considered to be the removal of all gross breast tissue, the nipple-areola complex, and the biopsy scar. The medical records were reviewed for the type of reconstruction, local and distant recurrence, tumor subtype and grade, and margins of resection. Specimen radiography was performed if the resection was close to the chest wall or mastectomy skin flaps. Close surgical margins were defined as tumor within 1 mm of the resection. All patients were followed up with clinical examination, and all selectively

underwent mammography of the reconstructed breast in the event of an abnormal clinical finding. By using the tumor size, surgical margins, and pathologic characterization, ductal carcinoma in situ cases were retrospectively classified according to the Van Nuys Prognostic Index Scoring System (Table I). It consists of three variables (margin width, tumor size, and pathologic characteristics), with a score of 1 to 3 given to each. These three scores are added for a maximum total score of 9, with higher scores representing a greater risk of recurrence.

#### RESULTS

##### All Patients

The study group comprised 221 consecutive patients. The patients' ages ranged from 24 to 81 years, with a mean of 42 years. The mean follow-up period was 9.8 years, ranging from 6 to 13 years. A total of 138 patients (62 percent) underwent TRAM flap reconstruction, 75 (34 percent) had reconstruction with an implant, and eight patients (4 percent) had reconstruction with a latissimus dorsi flap, with or without an implant. A contralateral prophylactic mastectomy with reconstruction was performed concurrently on 30 percent of patients (67 of 221). Review of the disease reports for the mastectomy specimens revealed that 44 patients (20 percent) had ductal carcinoma in situ, 118 (53 percent) had invasive ductal carcinoma, 24 (11 percent) had both ductal carcinoma in situ and invasive ductal carcinoma, nine (4 percent) had invasive ductal carcinoma with lobular carcinoma in situ, and 26 patients (12 percent) had invasive lobular carcinoma (Fig. 1).

The combined metastatic and local recurrence rates for patients with invasive carcinoma ( $n = 177$ ) for each type of reconstruction were 13 percent (14 of 110), 12 percent (seven of 60), and 14 percent (one of seven) for TRAM

TABLE I  
Van Nuys Prognostic Index Scoring System\*

Variables Scored	Score†		
	1	2	3
Size (mm)	≤15	16–40	≥41
Margins (mm)	≥10	1–9	<1
Pathologic classification	Non-high-grade without necrosis (nuclear grades 1 and 2)	Non-high grade with necrosis (nuclear grades 1 and 2)	High-grade with or without necrosis (nuclear grade 3)

\* Silverstein, M. J., Lagios, M. D., Craig, P. H., et al. A prognostic index for ductal carcinoma in situ of the breast. *Cancer* 77: 2267, 1996.

† These three scores are added for a maximum total score of 9, with higher scores representing a greater risk of recurrence.

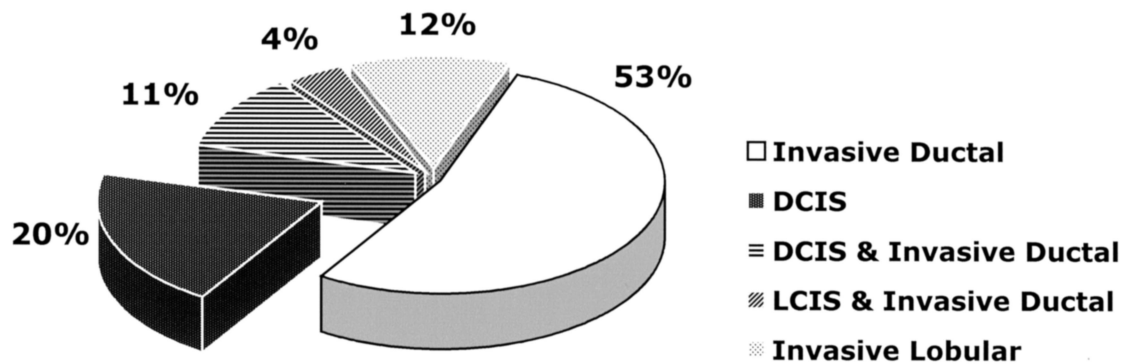


FIG. 1. Distribution of breast lesion disease ( $n = 221$ ). DCIS, ductal carcinoma in situ; LCIS, lobular carcinoma in situ.

flaps, implants, and latissimus dorsi flaps, respectively. There was no statistical difference in the recurrence rate between the types of reconstruction by chi-square analysis. Among the patients with invasive carcinoma, 6.8 percent (12 of 177) had metastatic recurrences and 5.6 percent (10 of 177) had local recurrences; all recurrences were invasive ductal carcinoma. No patient had both local and metastatic recurrence.

#### Ductal Carcinoma in Situ Only

The mean age of the 44 patients with ductal carcinoma in situ alone was 40 years (range, 27 to 72 years). The mean follow-up period for the group was 10.5 years (range, 6 to 13 years). Fifteen patients with ductal carcinoma in situ (34 percent) underwent a concurrent prophylactic mastectomy. The immediate reconstructions were performed with TRAM flaps in 28 patients (64 percent), 15 (34 percent) with implants, and a latissimus dorsi flap in one patient (2 percent). Axillary dissection was performed in 38 patients (86 percent), none of whom showed lymph node involvement.

Specimen radiography was selectively performed for lesions close to the skin or chest wall to ensure adequate resection of the ductal carcinoma in situ. Six patients had close surgical margins and one had a single focus of microinvasion.

The ductal carcinoma in situ tumor subtype was comedo in 27 patients (61 percent) and noncomedo in 17 patients (39 percent). The noncomedo ductal carcinomas in situ were categorized into five architectural subtypes: two papillary (5 percent), two micropapillary (5 percent), three cribriform (7 percent), five solid (11 percent), and five unclassified (11 percent) (Fig. 2). The ductal carcinoma in situ

were also rated according to Black's nuclear grade: 37 were intermediate-grade (84 percent), five were high-grade (11 percent), and two were low-grade (5 percent).

There were 13 patients (30 percent) with a Van Nuys Prognostic Index Scoring System of 3 or 4, 27 patients (61 percent) with a Scoring System of 5 to 7, and four patients (9 percent) with a Scoring System of 8 or 9 (Table II). There were no local or distant recurrences in any patient with ductal carcinoma in situ alone during the follow-up period.

#### DISCUSSION

The oncologic safety of skin-sparing mastectomy performed for ductal carcinoma in situ with immediate reconstruction is supported by our findings of no local recurrences during a mean follow-up period of 10.5 years.

#### Pathology

There are few reports describing the natural history of ductal carcinoma in situ. The local

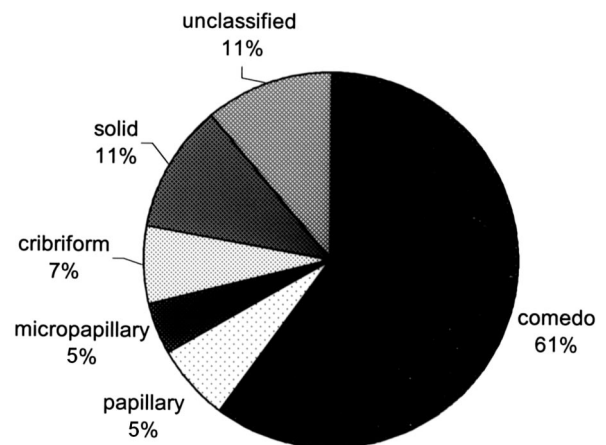


FIG. 2. Distribution of ductal carcinoma in situ subtypes showing a high incidence of comedo pathologic characteristics.

TABLE II

Distribution of Patients with Ductal Carcinoma in Situ ( $n = 44$ ) According to Their Risk of Local Recurrence as Determined by the Van Nuys Prognostic Index Scoring System Score

Risk of Recurrence	Score	( $n$ )
Low	3	8
	4	5
Intermediate	5	12
	6	6
	7	9
High	8	1
	9	3

recurrence rate of ductal carcinoma in situ following lumpectomy without radiation was found to be 43 percent in the National Adjuvant Breast and Bowel Project study.<sup>7</sup> Traditionally, ductal carcinoma in situ has been subdivided into comedo and noncomedo types, depending on the presence of necrotic cells. Noncomedo ductal carcinoma in situ is further classified into the cribriform, papillary, micropapillary, and solid subtypes. This classification may be confusing because ductal carcinoma in situ comprises a diverse group of lesions, and several different architectural types can coexist in one lesion. A system that correlates better with prognosis is grouping by nuclear grade, from low to high, according to the dominant cell type.<sup>8,9</sup>

Currently, the best predictor of local recurrence is the Van Nuys Prognostic Index Scoring System,<sup>10</sup> which is helpful in formulating a treatment plan: patients with a Scoring System of 4 or below are considered to have a low risk of recurrence and frequently undergo breast-conservation therapy, whereas patients with a Scoring System of 8 or 9 may be more appropriately treated by a mastectomy because of their high local recurrence rate (60 percent), regardless of irradiation. In our study, 9 percent of patients with ductal carcinoma in situ only had a Van Nuys Prognostic Index Scoring System of 8 or 9, and 61 percent had a Scoring System of 5 to 7; this represents a significant proportion of patients with a relatively high risk of local recurrence.<sup>11</sup> Despite this risk, there were no local recurrences in our study.

#### *Type of Follow-Up*

Most local recurrences of ductal carcinoma in situ occur superficially in the native breast skin and subcutaneous tissue resulting from incomplete excision of breast tissue or neoplasia or both.<sup>12</sup>

Follow-up after reconstruction, therefore, consists most often of clinical examination, with mammography performed if an abnormality is found during the physical examination. At our institution, routine mammography has not been included as part of the follow-up after breast reconstruction, partly because its role remains unclear. In addition, there are difficulties with false-positive findings caused by postoperative scarring, and the incidence of nonpalpable locoregional recurrence is low. Most investigators find a low cost-to-benefit ratio in using routine mammography for oncologic follow-up after breast reconstruction with myocutaneous flaps; however, no study has specifically addressed patients treated for ductal carcinoma in situ.<sup>13</sup>

Interesting insight into the issue of mammography following reconstruction is provided by a case series of local recurrences in four women who received skin-sparing mastectomy for ductal carcinoma in situ and reconstruction with TRAM flaps.<sup>14</sup> All four patients had multifocal ductal carcinoma in situ with high nuclear grades, three had close surgical margins (tumor within 1 mm of excised margin), and two patients had foci of microinvasion. Three of the four recurrences were detected by physical examination alone; one recurrence was detected by a screening mammogram ordered by the patient's primary physician. All recurrences were invasive ductal carcinomas. The authors suggested the implementation of routine postoperative mammography in patients who had high-grade, multifocal ductal carcinoma in situ, especially those with close surgical margins. This subgroup would have a Van Nuys Prognostic Index Scoring System of 8 or above, which identifies them as being at high risk for local recurrence. In our study, patients were followed up clinically; mammography was used selectively for patients with any suspicious findings during physical examination. This could lead to an underestimate of local recurrences by not detecting nonpalpable recurrences; however, it is not known what percentage of such nonpalpable local recurrences could be diagnosed by mammography.

#### *Length of Follow-Up*

It has been well established that the addition of radiation therapy after lumpectomy decreases the incidence of local recurrence of ductal carcinoma in situ.<sup>7</sup> Because ductal carcinoma in situ patients who undergo mastec-

tomy usually do not receive radiation therapy, a benchmark for assessing the length of follow-up needed to correctly assess the risk of local recurrence following skin-sparing mastectomy could be established by looking at studies that evaluate the recurrence rate of ductal carcinoma in situ treated by excision alone. One example is a study in which 28 patients who had small, noncomedo ductal carcinoma in situ that was excised by biopsy only were followed up for a mean of almost 30 years. During the first 16 years of the study, invasive ductal carcinoma was developed 3 to 10 years later (mean, 6.1 years) by seven patients in the same location as the previously detected ductal carcinoma in situ.<sup>15</sup> Invasive ductal carcinoma was developed by two additional patients between 20 and 30 years after the initial excisional biopsy, and extensive ductal carcinoma in situ was developed by one patient 25 years after the initial biopsy.<sup>16</sup> All recurrences were detected clinically. The recurrence rate was found to be 32 percent, with the overall risk of invasive carcinoma developing following excision of ductal carcinoma in situ in the 30-year period being nine times the risk of the general population developing invasive breast carcinoma. In another study, the local recurrence rate was 16 percent after lumpectomy alone for ductal carcinoma in situ (mean follow-up, 10.3 years), with the recurrences divided equally between ductal carcinoma in situ and invasive ductal carcinoma.<sup>3</sup> In our study, the mean follow-up was 9.8 years (10.5 years for those with ductal carcinoma in situ only), which seems to be an adequate amount of time to identify most recurrences, because the majority of recurrences in the aforementioned studies were found in the first decade of the follow-up period. Nevertheless, additional recurrences will likely develop with longer follow-up, and this group of patients will be monitored to provide long-term follow-up data.

#### Margin

The status of the lumpectomy margin in ductal carcinoma in situ is a strong prognostic factor for recurrence.<sup>17,18</sup> A margin is considered adequate if ductal carcinoma in situ is 1 mm or greater from the excision margin.<sup>19</sup> Because of the multifocal nature of ductal carcinoma in situ, local recurrence may not be an actual recurrence but rather residual, unresected disease. In our study, six patients with ductal carcinoma in situ alone had close (<1

mm) surgical margins; however, a recurrence during the follow-up period developed in no patient with ductal carcinoma in situ alone. The patients received close follow-up but did not undergo radiation therapy.

#### Axillary Dissection

Axillary lymph node dissection is no longer routinely used for the treatment of ductal carcinoma in situ, because the overall risk of axillary node metastasis is low.<sup>20</sup> During the collection, however, a significant number (86 percent) of the ductal carcinoma in situ only patients underwent axillary node dissection, and no positive nodes were detected.

#### CONCLUSIONS

In this relatively small population of patients who underwent skin-sparing mastectomy with immediate reconstruction for ductal carcinoma in situ, no clinically detectable local recurrence was found, despite a mean of 10.5 years of follow-up. Therefore, skin-sparing mastectomy with immediate reconstruction seems to be an oncologically safe option for these patients.

Charles E. Butler, M.D.  
 Department of Plastic Surgery  
 M. D. Anderson Cancer Center  
 1515 Holcombe Boulevard, Box 443  
 Houston, Texas 77030-4009  
 cbutler@mdanderson.org

#### ACKNOWLEDGMENTS

We thank Dr. Frederick Ames, Dr. Eva Singletary, and the late Dr. Stephen Kroll for their thoughtful insights on this subject.

#### REFERENCES

1. Schnitt, S. J., Silen W., Sadowsky, N. L., et al. Current concepts: Ductal carcinoma in situ (intraductal carcinoma) of the breast. *N. Engl. J. Med.* 318: 898, 1988.
2. Baker, L. H. Breast cancer detection demonstration project: Five-year summary report. *CA Cancer J. Clin.* 32: 194, 1982.
3. Dupont, E. L., Ku, N. N., McCann, C., and Cox, C. E. Ductal carcinoma in situ of the breast. *Cancer Control* 6: 264, 1999.
4. Cox, C. E., Hyacinthe, M., Gonzalez, R. J., et al. Cytologic evaluation of lumpectomy margins in patients with ductal carcinoma in situ: Clinical outcome. *Ann. Surg. Oncol.* 4: 644, 1997.
5. Kroll, S. S., Khoo, A., Singletary, S. E., et al. Local recurrence risk after skin-sparing and conventional mastectomy: A 6-year follow-up. *Plast. Reconstr. Surg.* 104: 421, 1999.
6. Rivadeneira, D. E., Simmons, R. M., Fish, S. K., et al. Skin-sparing mastectomy with immediate breast re-

- construction: A critical analysis of local recurrence. *Cancer J* 6: 331, 2000.
7. Fisher, E. R., Leeming, R., Anderson, S., Redmond, C., and Fisher, B. Conservative management of intraductal carcinoma (DCIS) of the breast: Collaborating NSABP Investigators. *J. Surg. Oncol* 47: 139, 1991.
  8. Holland, R., Peterse, J. L., Millis, R. R., et al. Ductal carcinoma in situ: A proposal for a new classification. *Semin. Diagn. Pathol* 11: 167, 1994.
  9. Lagios, M. D., Margolin, F. R., Westdahl, P. R., et al. Mammographically detected duct carcinoma in situ: Frequency of local recurrence following tylectomy and prognostic effect of nuclear grade on local recurrence. *Cancer* 63: 618, 1989.
  10. Silverstein, M. J., Lagios, M. D., Craig, P. H., et al. A prognostic index for ductal carcinoma in situ of the breast. *Cancer* 77: 2267, 1996.
  11. Silverstein, M. J. Ductal carcinoma in situ of the breast: Controversial tissues. *Oncologist* 3: 94, 1998.
  12. Slavin, S. A., Love, S. M., and Goldwyn, R. M. Recurrent breast cancer following immediate reconstruction with myocutaneous flaps. *Plast. Reconstr. Surg* 93: 1191, 1994.
  13. Puckett, C. L. Mammograms of the reconstructed breast. *Plast. Reconstr. Surg* 88: 482, 1991.
  14. Salas, A. P., Helvie, M. A., and Wilkins, E. G. Is mammography useful in screening for local recurrences in patients with TRAM flap breast reconstruction after mastectomy for multifocal DCIS? *Ann. Surg. Oncol* 5: 456, 1998.
  15. Page, D. L., Dupont, W. D., Rogers, L. W., et al. Intraductal carcinoma of the breast: Follow-up after biopsy only. *Cancer* 49: 751, 1982.
  16. Page, D. L., Dupont, W. D., Rogers, L. W., et al. Continued local recurrence of carcinoma 15–25 years after a diagnosis of low-grade ductal carcinoma in situ of the breast treated only by biopsy. *Cancer* 76: 1197, 1995.
  17. Schnitt, S. J., Abner, A., Gelman, R., et al. The relationship between microscopic margins of resection and the risk of local recurrence in patients with breast cancer treated with breast-conserving surgery and radiation therapy. *Cancer* 74: 1746, 1994.
  18. Frazier, T. G., Wong, R. W., and Rose, D. Implications of accurate pathologic margins in the treatment of primary breast cancer. *Arch. Surg* 124: 37, 1989.
  19. Holland, P. A., Gandhi, A., Knox, W. F., et al. The importance of complete excision in the prevention of local recurrence of ductal carcinoma in situ. *Br. J. Cancer* 77: 110, 1998.
  20. Silverstein, M. J., Gierson, E. D., Waisman, J. R., et al. Axillary lymph node dissection for T1a breast carcinoma: Is it indicated? *Cancer* 73: 664, 1994.