
Selection of an Appropriate Method of Breast Reconstruction: Factors Involved in Customizing Breast Restoration

Zachary Menn and Aldona Spiegel

Additional information is available at the end of the chapter

<http://dx.doi.org/10.5772/56333>

1. Introduction

When considering breast reconstruction, the patient's perception essentially determines the success, or failure, of the reconstruction. It is important for the surgeon to ask questions and listen to the patient to determine what expectations the patient has for the final results. In the past, the goal of breast reconstruction was to help a patient look "normal" in clothing. With the advancements in technique and technology, we have raised the bar so that patients look good not only in clothing, but also when they see themselves undressed in the mirror. In this chapter we will discuss how to match a breast reconstruction candidate with the procedure that will provide the best result.

2. The defect

As with any reconstructive procedure, the first step is the evaluation of the defect to be reconstructed. The size, shape, and quality of the defect are all important factors and are resultant from the type of mastectomy performed. Radical, modified radical, skin sparing, areolar sparing, and nipple sparing mastectomies all create a different defect with different requirements for reconstruction. It is important to determine if the defect simply requires volume replacement or if there is a component of skin that needs to be replaced. It is vital to examine the skin flaps remaining after the mastectomy for any damage from radiation or the surgery. If the skin is not viable or has radiation damage it may be unusable in the reconstruction and require resection. The amount and type of volume replacement needs to be estimated by determining the final preference for breast size of the patient.

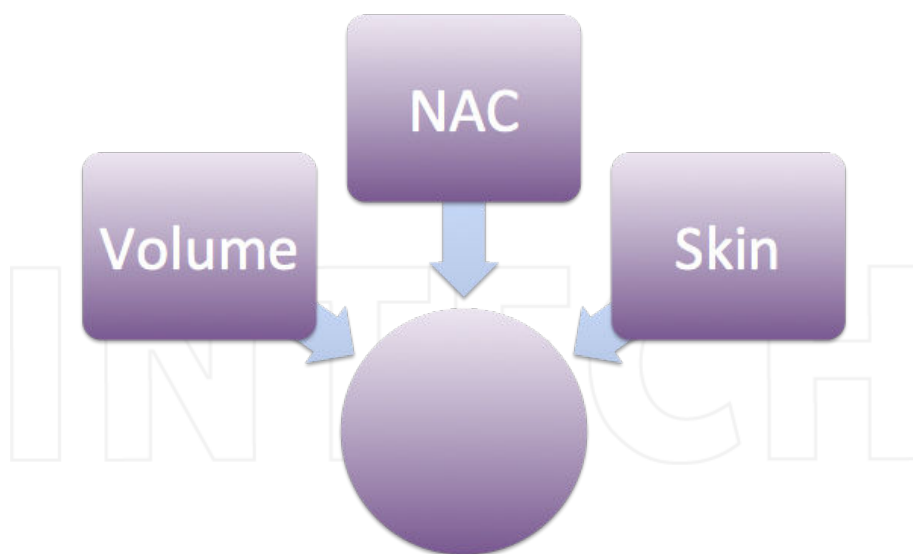


Figure 1. The type of reconstruction should be chosen based upon what is missing following mastectomy including breast volume, nipple-areolar complex and/or skin.

3. The patient

3.1. Patient assessment

During the patient assessment at the initial visit, there are many important pieces of information that should be gathered during the history and physical.

Physical Exam: The size of the breast(s) to be reconstructed needs to be considered in your planning, as well as whether the reconstruction will be unilateral or bilateral. Bilateral reconstruction and larger breasts will require a larger volume of donor site tissue which may limit some reconstructive options. Examine the breasts for scars, asymmetry, ptosis, nipple position and skin quality making sure to point out any irregularities to the patient. The distribution and amount of excess soft tissue should also be noted. First, examine the abdomen for adipose tissue volume. Next examine the back, buttocks and inner thighs for laxity and soft tissue volume.

Oncologic status: The patient's oncologic status should be requested to determine what prior treatments they already completed and if there is a future need for radiation. It is also important to determine if the prior treatment was adequate, particularly if the patient was referred from an outside facility. Additional radiologic studies may be necessary to make this determination. If the patient has not received adequate treatment, there may be future need for radiation, which might change the approach to reconstruction.

Medical history: A thorough medical history is important before considering a type of reconstruction because some medical and social issues may be contraindications to certain reconstructive procedures. Some contraindications to free flaps include: smoking, diabetes, obesity, peripheral vascular disease, clotting disorders, and advanced age. Breast implant manufacturers caution that the safety and effectiveness of these devices have not been established in patients with autoimmune diseases (such as lupus and scleroderma), a compromised immune system (receiving immunosuppressive therapy) or patients with conditions or medications which interfere with wound healing ability (such as corticosteroid therapy or poorly controlled diabetes) or blood clotting (such as coumadin therapy).¹ Each of these factors should be inquired about, as they have an impact on procedure selection.

Surgical history: Surgical and obstetric history should be taken. All C-sections, abdominoplasties, liposuction procedures, traumas, abdominal surgeries, and any scar severing the blood supply to specific areas of excess soft tissue (abdomen, buttock, back and thigh) should be noted as this will determine which body areas are available as a donor site for reconstruction.

Family and Social history: Age, marital status, family history and social support may greatly impact the decision of which type of reconstruction best fits a specific patient. A young, thin patient with a strong family history of breast cancer, BRCA positive, having prophylactic nipple sparing mastectomies, may be more suited for an implant only reconstruction due to possible lack of excess soft tissue that may be seen more prominently in an older individual. Social support is also important to consider as well as activity level requirements in employment, allotted time off work, and home responsibilities. This is why it is important to discuss the patient's social situation and support network before deciding on a type of breast reconstruction.

3.2. Patient expectations and goals

A conversation with the patient should be had to determine the size of the breast(s) to be reconstructed and decide whether it will be a unilateral or a bilateral reconstruction. At this time, it is also important to assess the patient's perception of the contralateral breast. Some patients may need bilateral reconstruction due to the spread of the disease and require a mastectomy, while others may opt for a prophylactic mastectomy due to a genetic predisposition for breast cancer. Others may not need a mastectomy on the contralateral breast, but some symmetry surgery may still be necessary. Autologous reconstruction can typically match the contralateral breast, while implant only reconstruction makes matching the native breast more difficult. The patient should be counseled at the initial visit about the possibility of surgery on the contralateral breast even though it is unaffected by the cancer. Another patient factor, possibly the most important to consider, is the patient's preference of reconstruction. It is the surgeon's job, as the expert, to explain the reconstructive options, educate the patient as to the best option for their specific situation, and ultimately let the patient decide upon the option with which they are most comfortable.

3.3. Patient commitment

It is vital that patients who expect to undergo autologous reconstruction commit to a healthy lifestyle and prepare their body for the major surgery that is breast reconstruction. Smoking cessation and weight loss are important, if necessary. There is also a commitment after the surgery to follow up at least once and restrict activities for four to six weeks after autologous reconstruction.

4. The surgeon

The surgeon plays the major role in the success of the surgery. As the choices for breast reconstruction have evolved, it has been noted that specialized microsurgical procedures have a “learning curve” and are more successful when performed by a surgeon or team with a higher volume of cases.²

4.1. Types of reconstruction

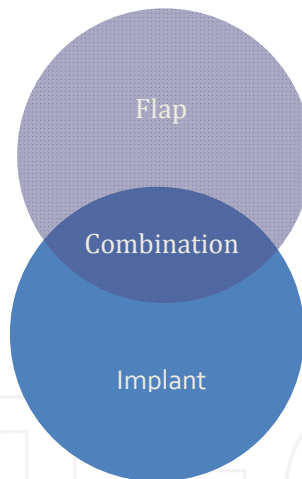


Figure 2. Breast reconstruction can be broken down into two categories: autologous flap reconstruction and implant-based reconstruction. However, in some cases, a combination of the two may provide the best result.

4.2. Tissue expanders/implants

This is a popular choice for breast reconstruction; it involves no donor site incision and minimal recovery time. There is no need for a donor site, so this type of reconstruction is suitable for patients who may have been ruled out for other reconstructions due to an insufficient donor site. This type of reconstruction is also preferable for older and less healthy patients who may not be able to tolerate a lengthier, flap-based reconstructive procedure. The surgeon needs to

consider the timing of implant placement if future radiation therapy is required. The sequence and timing of implant placement after radiotherapy influences the complication rate. Reconstructive failure is significantly higher if the time between completion of radiotherapy and implant exchange is less than 6 months.³ In many cases where the mastectomy has been radiated, implant only reconstruction is not an option due to higher complication rates and the need for skin replacement. The use of acellular dermal matrices can be helpful with implant only reconstruction, but in the end it is the surgeon's preference. With this option, the patient needs to be counseled about the risk and benefit of implants versus autologous flap reconstruction. The short term risks are reduced since the recovery does not involve a donor site. However, long term risks are higher as inherent to the implant device.

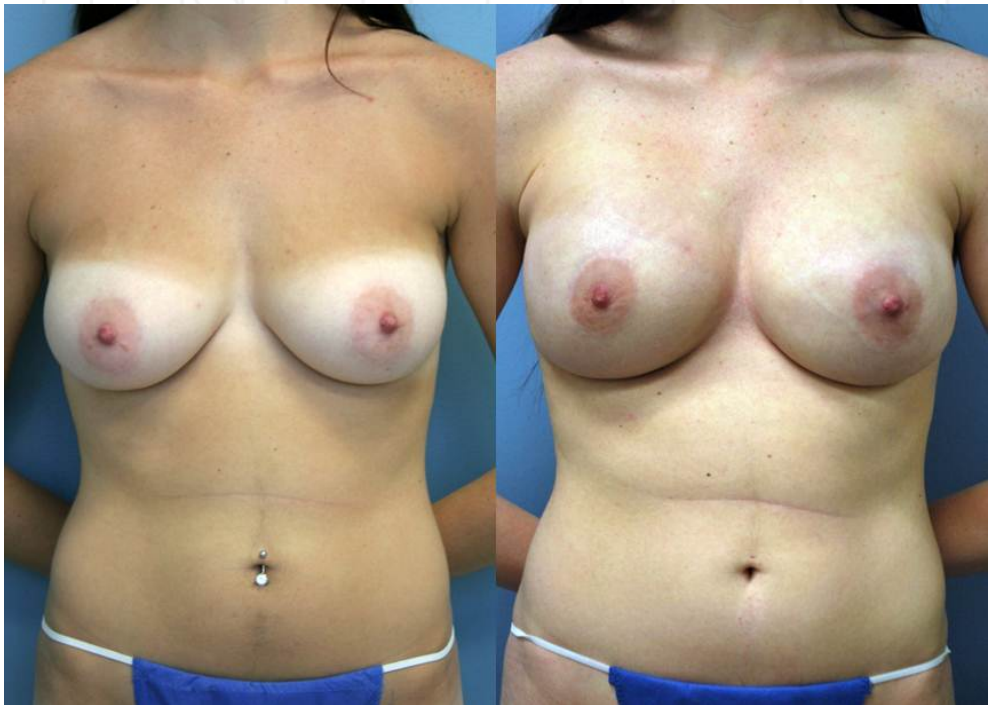


Figure 3. Preoperative and postoperative views of a bilateral tissue expander and implant based breast reconstruction.

4.3. Autologous flaps

4.3.1. Abdominal flaps

When examining a patient for breast reconstruction, a pinch test will help to estimate the amount of excess tissue available. In general, an average patient with a BMI greater than 20

and a history of at least one pregnancy should have enough abdominal tissue for a unilateral B to C cup breast reconstruction. The most important requirement for this flap is patent vessels in the lower abdomen. Previous abdominoplasty and extensive liposuction are contraindications to these flaps due to the disruption of the underlying blood supply. On examination, look for any abdominal scars. Scars may indicate a previous severance of the subcutaneous vasculature. Vessel patency can be determined by CTA or use of Doppler ultrasound.

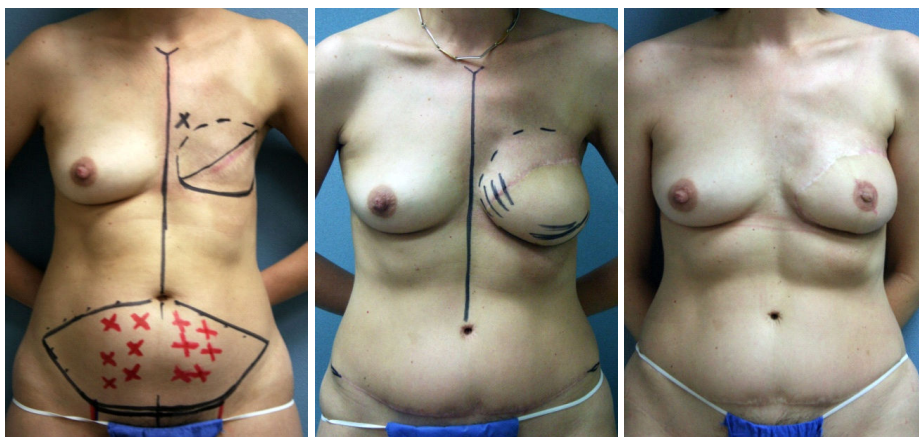


Figure 4. Preoperative markings and postoperative views of an abdominal perforator-based free flap breast reconstruction.

4.3.1.1. DIEP

This is the first choice for autologous reconstruction in our Center. The indications for the DIEP are similar to the indications for SIEA and TRAM as far as the need for excess lower abdominal tissue. Optimal perforator selection is key, as it impacts flap perfusion and muscle preservation. Imaging is helpful to determine if blood supply is patent and to map out the best perforator vessels. The DIEP flap may be combined with an implant to increase volume for a better size match with the contralateral breast or to improve the aesthetic outcome.

4.3.1.2. SIEA

Much like the DIEP flap, the SIEA flap requires excess lower abdominal tissue but is not a perforator flap. The difference between the two flaps is the blood supply with the SIEA using the superficial inferior epigastric artery to perfuse the flap. The availability of the SIEA has been shown to be variable. Drs Taylor and Daniel demonstrate that the SIEA was not present in 35% of their 100 cadaveric dissection specimens.⁴ More recent literature by Stern and Nahai showed that 87% of subjects had an identifiable SIEA, while Reardon et al found the SIEA in 90% of subjects.⁵⁻⁷ Specific to the survival of the SIEA flap is the need for a donor artery of 1.5 mm diameter or greater described by Spiegel et al.⁸ This study found that in 278 clinical

dissections over a 3 year period, approximately 31% of cases had identifiable superficial inferior epigastric arteries that were larger than 1.5 mm in diameter. The infrequent availability of a sufficiently sized artery limits the use of this type of reconstruction.

4.3.1.3. TRAM

The TRAM flap can be used as a pedicled or free flap. The use of this flap depends on the surgeon and the situation. Preserving the muscle has become more ubiquitous. The DIEP flap has become more of the standard of care as more residents are being taught this procedure. The use of a pedicled TRAM flap may be appropriate if a free flap is not possible in the selected patient.

4.3.2. *Latissimus flap*

The latissimus dorsi flap is a good second choice flap if the lower abdomen is inadequate, unavailable, or if the patient is opposed to an abdominally-based reconstruction. The volume of this flap is dependent upon the amount of soft tissue available on the back and skin laxity. Skin laxity is important for creating a skin island with the flap to replace skin deficit left from the mastectomy.

The latissimus dorsi flap may be muscle and soft tissue alone, or if skin is needed, it can be taken as a musculocutaneous flap. If a large amount of soft tissue is needed, an extended latissimus myocutaneous flap can be used in order to include more fat with the flap. Due to the limited volume that is provided, even with the extended latissimus dorsi myocutaneous

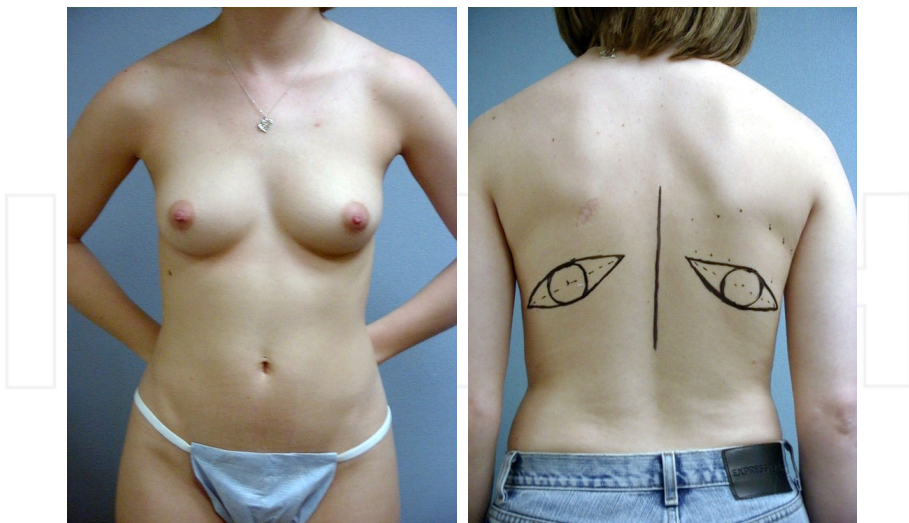


Figure 5. Anterior and posterior views of a preoperative bilateral latissimus dorsi breast reconstruction patient with markings.

flap, these flaps are usually combined with an implant to produce an adequate breast size. This flap generally provides donor site scars that are easily hidden in clothing.

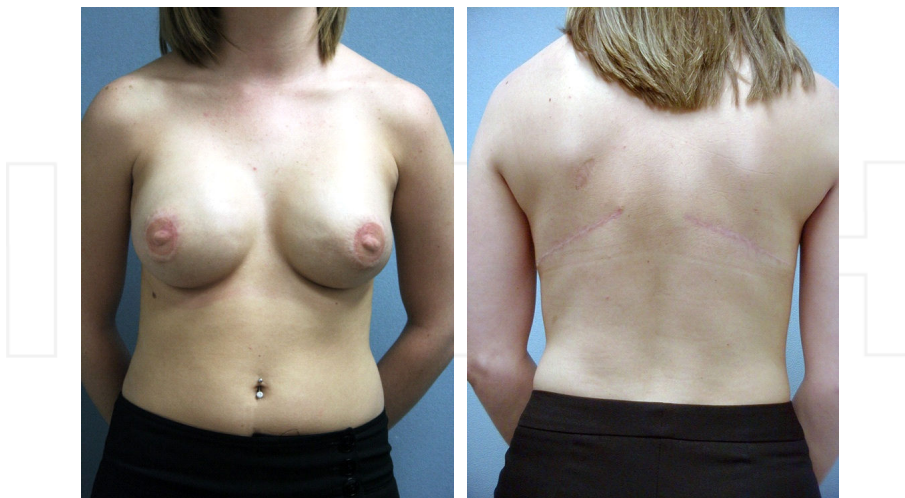


Figure 6. Anterior and posterior views of a postoperative bilateral latissimus dorsi breast reconstruction patient.

4.3.3. Gluteal flaps

Gluteal flaps are an alternative choice for autologous reconstruction when an abdominal donor site has been ruled out due to insufficient tissue or compromised blood supply from previous surgery or scarring. Another reason for choosing this flap is simply an excess amount of available soft tissue in the gluteal region. Patient preference plays a significant role in the selection of this flap because even if the patient has enough gluteal tissue to create a breast, they may like their current gluteal shape and may not be willing to change it.

The gluteal myocutaneous flap was described for breast reconstruction by Fujino in 1981.⁹ Since that time, the gluteal flap has evolved into the SGAP, IGAP, and scGAP flaps. These perforator flaps are far more popular now due to the decreased donor site morbidity. Gluteal artery perforator flaps have become a well-liked alternative when the first line abdominal flaps are not available.

The choice of the SGAP and IGAP flaps depend on the patient and surgeon. Patients who wish to get rid of “saddlebags” while maintaining superior fullness of the buttocks may benefit from the IGAP which hides its scar in the inferior gluteal fold; however some reports state that the lateral edge of the scar may be visible in a bathing suit. The SGAP on the other hand, conceals its scar within most bathing suit bottoms at the expense of removing some of the superior fullness of the buttocks. The surgeon must decide which area has sufficient tissue to reconstruct the breast. The patient must also decide which scar/volume deformity they prefer. Working together the surgeon and patient must come to an agreement as to what would be best for the patient.

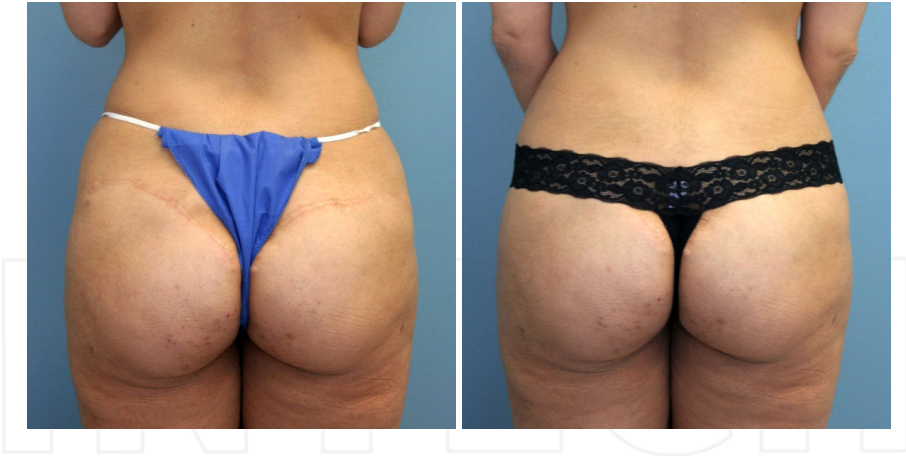

Figure 7. Postoperative view of the donor site scar from a superior gluteal artery perforator (SGAP) flap and a view showing the scar easily concealed by the patient's underwear.

4.3.4. Other flaps

4.3.4.1. TUG Flap

The TUG flap is best for patients with excess soft tissue in the medial thigh. This flap is indicated when other, more popular, flap donor sites have been ruled out due to insufficient tissue, compromised blood supply from previous surgery or scarring, or patient preference. This flap provides a well hidden donor site scar in the groin crease. This flap requires a surgeon familiar with this procedure.

4.3.4.2. PAP Flap

The PAP flap uses excess soft tissue of the medial thigh. This flap provides a well hidden donor site scar in the infragluteal fold. This flap is indicated when other donor sites have been ruled out due to insufficient tissue, compromised blood supply from previous surgery or scarring, or patient preference. Patient preference for this site is not the overall deciding factor as this flap also requires a surgeon who is familiar with this relatively new technique.

5. Other breast reconstruction techniques

5.1. Lipomodeling

Lipomodeling can be a sole mode of reconstruction for some surgeons who perform total breast reconstruction with ATF (autologous fat transfer) with or without the addition of an external tissue expander device; however, most surgeons use lipomodeling as an adjunct. It is useful

for correcting of size mismatch and contour deformities, as well as the improvement of aesthetics. It can also be used to improve the quality of skin if the breast has been previously irradiated.

6. Summary

A focus on aesthetic refinements beyond flap survival is important for optimal breast reconstruction results. Good communication with general surgeons during mastectomy planning helps to provide a better cosmetic result and can make a reconstructive surgeon's life a lot easier. Additionally, the development of the Breast Q has allowed us to better analyze these results by quantifying the patient's opinion of the outcome. By selecting a method of breast reconstruction that best fits an individual patient, a surgeon can improve his/her odds of great results, from both the surgeon's and the patient's point of view, before the first cut is made.

Author details

Zachary Menn and Aldona Spiegel

Weill Cornell Medical College, The Methodist Hospital, Houston, Texas, USA

References

- [1] Mentor CorpMemoryGel Breast Implants Product Insert Data Sheet. August 2010. (Web site) Available at: www.mentorwllc.com/Documents/gel-PIDS.pdf. Accessed November 6, (2012).
- [2] Massey, M. F, et al. Perforator flaps: recent experience, current trends, and future directions based on 3974 microsurgical breast reconstructions. *Plast Reconstr Surg.* (2009). Sep; , 124(3), 737-51.
- [3] Peled, A. W, et al. Increasing the time to expander-implant exchange after postmastectomy radiation therapy reduces expander-implant failure. *Plast Reconstr Surg.* (2012). Sep; , 130(3), 503-9.
- [4] Taylor, G. I, & Daniel, R. K. The anatomy of several free flap donor sites. *Plast Reconstr Surg.* (1975). Sep; , 56(3), 243-53.
- [5] Stern, H. S, & Nahai, F. The versatile superficial inferior epigastric artery free flap. *Br J Plast Surg* (1992). May-Jun; , 45(4), 270-4.

- [6] Reardon, C. M, Ceallaigh, O, & Sullivan, S, O. ST. An anatomical study of the superficial inferior epigastric vessels in humans. *Br J Plast Surg.* (2004). Sep;, 57(6), 515-9.
- [7] Wolfram, D, Schoeller, T, Hussi, H, & Wechselberger, G. The superficial inferior epigastric artery (SIEA) flap: indications for breast reconstruction. *Ann Plast Surg.* (2006). Dec;, 57(6), 593-6.
- [8] Spiegel, A. J, & Khan, F. N. An intraoperative algorithm for use of the SIEA flap for breast reconstruction. *Plast Reconstr Surg.* (2007). Nov;, 120(6), 1450-9.
- [9] Fujino, T, Abe, O, & Enomoto, K. Primary reconstruction of the breast by free myocutaneous gluteal flap. *Int Adv Surg Oncol.* (1981). , 4, 127-43.

INTECH

INTECH

